

**BJMHR**

British Journal of Medical and Health Research

Journal home page: www.bjmhr.com

Study of Mycotic Keratitis –Clinical Presentation, Diagnosis, Complication and Management

Gajraj Singh Gurjar^{1*}, Laxman Kumar²**1.(M.B.B.S.,M.S. Ophthalmology R.I.O.Bhopal) At Present –Medical Officer , District Hospital , Morar (Gwalior , M.P.)****2.DR. Soni (M.B.B.S.,M.S. Ophthalmology R.I.O.Bhopal) At present –Medical officer J.P.Hospital ,Bhopal**

ABSTRACT

According to the World Health Organization, corneal diseases are a major cause of vision loss and blindness, second only to cataract in overall Importance. A study of recent epidemiological trends in case of fungal corneal ulcer. To study the Precipitating and predisposing factors for fungal corneal ulcer. 3. To study the clinical profile of fungal corneal ulcer. Thirty consecutive cases of presumably fungal corneal ulcers admitted in hospital over a period of one year were included in the study. The presumptive diagnosis was based on clinical features and history. The diagnosis was then confirmed by KOH preparation and culture. It was found that fungal corneal ulcer are common in people of 40-60 year and more common in male. Fungal corneal ulcer occur mostly in farmer but in urban area because of over use of topical antibiotics and steroid, fungal ulcer also very common and in urban young population who wear contact lens, corneal ulcer is common finding. Due to vegetative trauma in rural area and due to over use of topical antibiotics and steroid fungal ulcer is very common problem in urban population.

Keywords: Cornea, fungal infection, corneal ulcer, keratitis.

*Corresponding Author Email: dr.gajrajgurjar@gmail.com

Received 2 June 2016, Accepted 26 June 2016

INTRODUCTION

Mycotic keratitis is an important ophthalmologic problem causing preventable visual disability. Worldwide, the reported incidence of mycotic keratitis is 17% to 36%. In India, it is 44% to 47%.

Anderson, Roberts Gonzalves and Chick (1959)¹ and later Forster R.K., Rebell G² have reported infection of cornea by fungi.

Mycotic keratitis is a serious ocular infection, which requires urgent diagnosis and appropriate treatment.

Predisposing factors - for Mycotic keratitis

Common predisposing factors are: chronic ocular surface disease, long term use of topical steroids (often in conjunction with prior corneal transplantation), contact lens wear, systemic immunosuppressant and diabetes. Filamentary keratitis may be associated with trauma, often relatively minor, involving plant matter or agricultural tools .

Complication

The general course of the lesion is slow and torpid, leaving an extensive ulcer. Healing tends to follow after the sequestrum is discarded. Subjective symptoms are usually slight and corneal vascularisation is not seen. Pathologically , then fungal hyphae are seen to invade the cornea

MATERIALS AND MATHOD

The present study was carried out on outdoor and indoor cases of Regional Institute Of Ophthalmology, Gandhi Medical College Bhopal; in technical collaboration with department of microbiology, Gandhi medical college, Bhopal .Thirty consecutive cases of presumably fungal mycotic keratitis over a period of one year were included in the study. presumptive diagnosis was based on clinical features and history. The diagnosis was then confirmed by KOH preparation and culture.

Clinical features:-

The presumptive diagnosis was based on the following clinical features:

A dry looking, crumbly, raised slough. A shaggy or created border of the ulcer, Satellite lesions, Hypopyon, Immune ring (corneal ring) beyond the edge of the ulcer, Radiating folds, Endothelial plaques in the center of the cornea.

Examination of the Eye:

The visual acuity was recorded by snellen's chart. The anterior segment was examined with the help of a torch and binocular loupe. Slit lamp examination of the eyes was also done. Clinical characteristics of the Ulcers like number, site, size, presence or absence of, satellite lesions, vascularisation , corneal edema or radiating folds were noted.

Grade of Ulcer:

Schematic diagrams of the ulcer were drawn showing-

- (1). Size after flourescine staining
- (2). Corneal haze around it and
- (3). Depth

The ulcer were graded on a scale of 100 points by allotting points to each one of the above three characters as follows:

(I). size of ulcer:-

- | | |
|-----------------------------|-----|
| (a) less than 33% of cornea | 10% |
| (b) 33%-66% of cornea | 20% |
| (c) more than 66% of cornea | 30% |

(ii). Corneal haze :-

- | | |
|-----------------|-----|
| (a) slight | 10% |
| (b) appreciable | 20% |
| (c) significant | 30% |

(iii). Depth of ulcer :-

- | | |
|---|----|
| (a) superficial (epithelial and superficial stroma) | 10 |
| (b) deeper stroma | 20 |
| (c) desmetocoel | 30 |
| (d) perforation | 40 |

For example if an ulcer involved 50% of cornea with an appreciable haze around it, and a desmetocole was present, then the grade of ulcer was :

$$\{ 50\% \text{ cornea- } 20\} + \{ \text{appreciable haze- } 20\} + \{ \text{desmetocoel - } 30\} = \text{grade } 70$$

Investigations:

The following investigations were done in all the patients:

1. Flourescine staining- staining was done with sterile flourescein-strips(floure-stain) kept in the lower fornix for one minute. The excess of stain was washed and then the extent of ulcer was noted.
2. Syringing :- lacrimal sac syringing was carried out under surface anaesthesia with 4% lignocaine hydrochloride. Regurgitation, if any, whether clear, mucoid or mucopurulent was noted.
3. KOH preparation of corneal scraping :-

The material for examination was taken from the margins and base of the ulcer and put on a clean slide. One drop of freshly prepared 10% KOH was put on it and clean cover slip was added. Finger-nail polish was applied to all the sides of the cover slip

for sealing. The slide was then examined under low power of a microscope taking precaution that the condenser is racked down to reduce the light reaching the objective.

The slide was examined for any fungal hyphae, budding cells or large cells with endospores. If fungal hyphae were not seen, the slide was again examined after twenty four hours to allow poor germination of hyphae from the spores.

Collection of swabs for culture :

smooth bamboo sticks of about 165mm length were taken and swabs prepared with the help of absorbent cotton. The swabs were then put in test tubes which were then plugged and sterilized by placing in hot air oven at 160 °C for 1 hour. They were then stored in a refrigerator.

The swabs so collected were implanted in the culture medium in two test tubes. The swabs were pressed in the slants so that they were lodged in the deeper layers of the medium. The culture tubes were then incubated at room temperature up to 10 days for growth of fungus.

Identification of fungus :-

(Ajello, Georg, Kaplan and Kaufman)³

The fungus from the culture tube was placed in a mounting fluid before observing under microscope. The mounting fluid (Lactophenol cotton blue) was composed as:

Formula	Quantity
Phenol (crystals)	20 gms
Lactic acid	20 gms
Glycerol	40 gms
Distilled water	20 ml

Cotton blue stain 0.05 gm. Was added after dissolving the above mixture under hot water.

A loopful of culture was taken and put in a drop of mounting fluid on a clean glass slide and teased with a pointed needle. A cover slip was added and then it was observed under a microscope.

THRAPEUTIC REGIME:-

Local :

Medical :

1. Atropine drops 1% were put .
2. Broad spectrum antibiotics drops and ointments were applied 3 times daily.
3. Sodium sulphacetamide 30% 2 hourly. Instillation was added.
4. Protection by pad only during day to facilitate Topical medication, and pad and bandage at night was done.

Surgical: Surgical procedures were adopted only if needed.

1. Carbolisation with 100% carbolic acid.
2. Paracentesis.
3. Therapeutic keratoplasty to save the eye

General :

1. Sulphonamide and/or antibiotics.
2. Supportive – analgesics.
3. Diamox in cases of secondary glaucoma or desmetocoele.
4. Non steroid anti inflammatory drugs,
5. vitamin a and c and b-complex tablets

Follow Up :

The response to treatment was noted by clinical assessment and more specifically by fluorescent staining of cornea. Regular follow up was done of all the patient during their hospital stay. The first follow up was done on 3rd day and subsequently every 5th day till the ulcer healed as seen by fluorescent staining or an operative procedure was adopted.

RESULTS AND DISCUSSION

Table 1: Incidence and nature of topical medication

Treatment taken	No. of cases	percent
Antibiotic	3	10.0
Antibiotic & steroid	11	36.6
Home remedies	3	10.0
Unknown medication	9	30.0
No Treatment	4	13.3
Total	30	

86.6% patients had used one from of medication or another. Maximum number of patients gave a history of using an antibiotic –steroid combination (36.6%). The next category was of those patients who did not know which medication they had used, but majority amongst them gave history of initial relief following medication, but they did not become symptom –free (30%). While 10% each of patients gave a history of using an antibiotic or a home remedy, 13.3% did not avail of any form of treatment before reporting to the hospital.

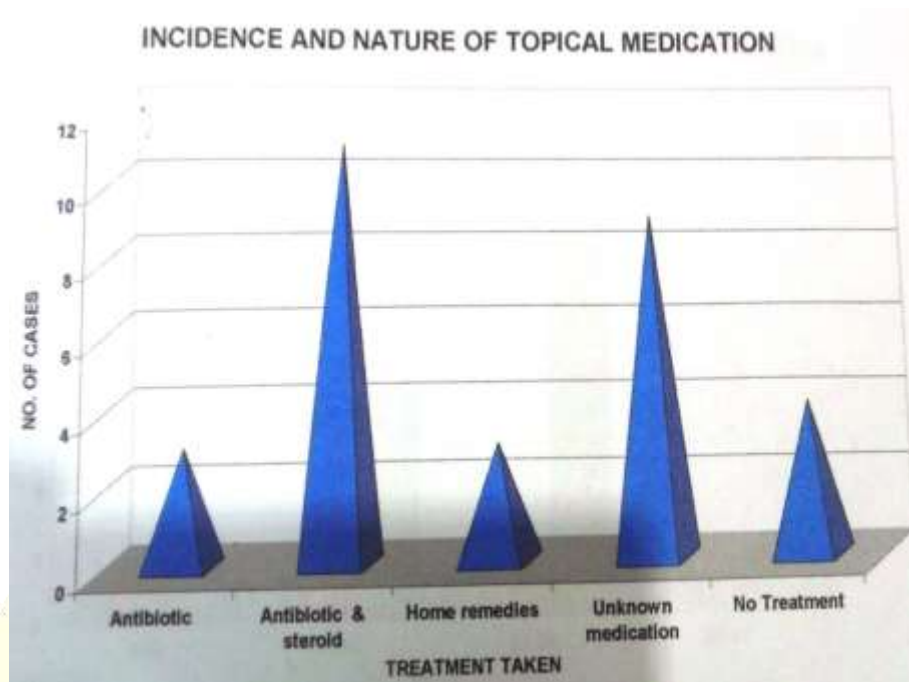


Figure 1: Incidence and nature of topical medication

Table 2: Time interval between injury and availing hospital facilities

Days	Urban	Rural	Total	Percent
0-10	1	1	2	6.6
11-20	8	6	14	46.6
21-30	-	13	13	43.3
31-40	-	1	1	3.3

While most patient (90%) availed hospital facilities between 11 to 30 days, the majority of those who came to the hospital between 11-20 day were urban. while most rural patients came to hospital later than that i.e. between 21-30 days.

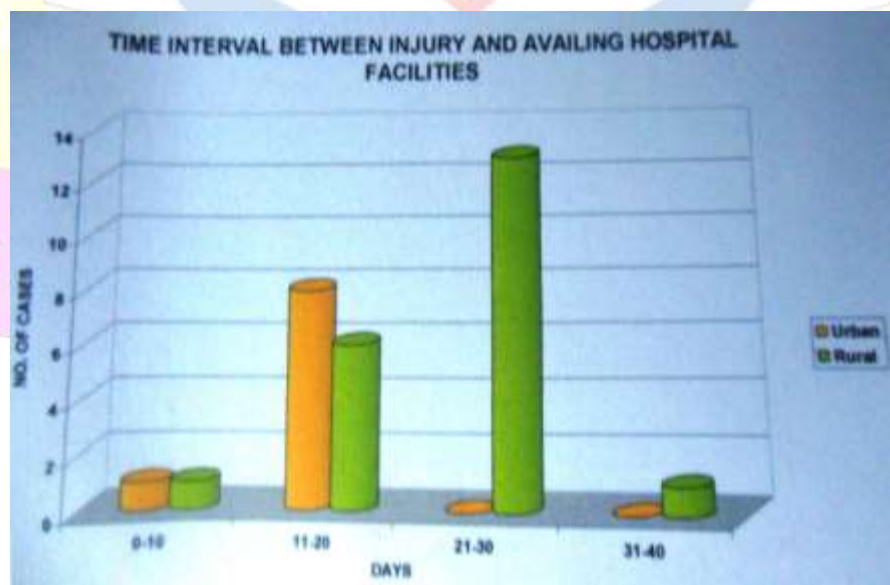


Figure 2: Time interval between injury and availing hospital facilities

Table 3: Clinical features and associated findings

Findings	No. of patients	Percent
Slough	30	100
Hypopyon	25	83.3
Intraocular Tension -		
Normal	24	80.0
Raised	5	16.6
Lowered	1	3.0
Satellite lesions	18	60.0
Vascularization	12	40.0
Perforation	1	3.0
Trachoma	24	80.0

Table 4: Site of corneal involvement

Site	No. of patients	Percent
Central	29	96
peripheral	1	4

Overwhelming majority of keratomycosis had central corneal ulcer. Only one case of urban area that had a history of foreign body in the eye had a peripheral ulcer which resembled a herpetic ulcer in configuration.

Table 5: Incidence of grade of ulcer

Grade of ulcer	No. of patients	Percent
40	3	10.0
50	7	23.3
60	8	26.6
70	8	26.6
80	-	0.0
90	3	10.0
100	1	3.0

Majority of mycotic ulcers (76.5%) were in 50-70 grade. Surprisingly, although no ulcer was found to be in grade of 80, 13 % ulcers were found in grade 90-100.

Table 6: Relation between grade of ulcer and clinical response

Grade	No. of cases	Percent	Average time taken (days)	
			Clinical improvement	Healing
40	3	10	8	24.6
50	7	23.3	9.8	26.5
60	8	26.6	11.12	33.0
70	8	26.6	12.16.	36.0
80	-	0	-	-
90	3	10	-	-
100	1	3	-	-

Maximum number of mycotic ulcers were in the grade of 50 to 70 when first seen. Grade 100 ulcer was the most uncommon (3%). Not a single ulcer was seen in grade 80, while 13% ulcers were in grade 90 and 100.

With increasing grade of ulcer, the average time taken for clinical improvement as well as complete healing was also more. While ulcer up to grade 50 healed within four weeks. Those with grade 60 and above required about five weeks. Clinical improvement was not observed in grade 90 and 100 ulcers.

Table 7: Incidence of KOH and culture positive ulcers

Ulcer scraping	No. of cases	Percent
10% KOH positive	17	58.6
Culture positive	29	96

Majority of cases which were presumed to be keratomycosis on the basis of clinical features, symptoms and suggestive history showed growth of fungus on culture of corneal swabs. In 24.1% of these cases, examination of corneal scraping with 10% KOH did not reveal any fungal hyphae or spores under microscope.

Table 8: Incidence of different type of fungi

Type of fungus	Culture			
	Affected eye	Percent	Unaffected eye	percent
Aspergillus fumigates	24	80	13	43
Aspergillus niger	4	13	-	-
Alternaria	1	3	-	-
No growth	1	3	17	57

While 96% corneal ulcer swabs were positive for fungus on culture, only 43% conjunctival swabs of unaffected eyes showed fungal growth on culture. Most commonly encountered fungus was aspergillus followed by aspergillus niger and Alternaria. No fungus could be recovered from one case.

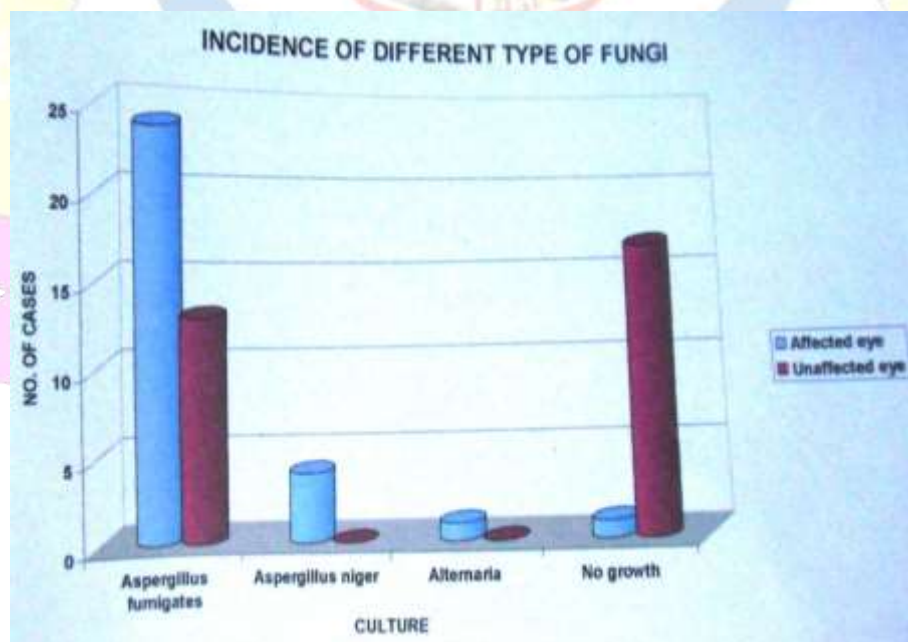


Figure 3: Incidence of different type of fungi

Table 8: between previous treatment taken and grade of ulcer

Therapeutic status	Grade of ulcer	Mean grade
Antibiotic	>= 50	63.3
Antibiotic and steroid	>= 50	67.2
Home remedies	>= 50	53.3
Unknown medication	>= 50	63.3
No Treatment	<= 50	42.5

All those patients who gave a history of medication just before or after the ulcer formed came to the hospital with ulcers which were more than or equal to grade 50. those patients who had not taken any treatment had ulcers less than or equal to grade 50. Moreover, patients who had used antibiotic- steroid combination had the highest mean grade of ulcer (67.2) and patients with no history of treatment had the lowest mean grade of ulcer (42.5).

Table 9: Relation between vascularisation and healing of ulcers

Vascularization	Ulcer		Healing	
	Number	percent	Number	percent
Absent	18	60.0	17	94.5
Moderate	2	6.6	1	50
Marked	10	33.3	5	50
Total	30		24	

In 60% ulcers . Vascularization of cornea was not seen. These type of ulcers had a healing rate of 94.5%. In 40% (Moderate 6.6 % + Marked 33.3 %) ulcers, vascularisation of cornea was seen. These ulcers had a healing rate of only 50 %. There appears to be some relationship of mycotic ulcers.

Table 10: Analysis of grade 50 ulcer

No of ulcer	Clinical Improvement (days)	Healing (days)	Type of fungus	History of treatment
1	8	23	A. Fumigates	Not taken
4	8	28	A. fumigates	Taken
1	13	28	A. niger	Taken
1	13	38	Alternaria	Taken

Five ulcers were infected with A. fumigates but no treatment was taken in only one case. This case healed in the shortest time. Other four ulcers in which history of previous treatment was present took longer to heal although infected with the same species. One case was infected with A.niger . One case was infected with alternaria and took longer to show clinical improvement and the longest time for healing.

Table 11: Relation between grade of ulcer and resultant opacity

Grade of ulcer	Resultant corneal opacity		
	Nebular	Macular	Leucomatous
40	2 (66.6%)	1 (33.3%)	-
50	-	6 (85%)	1 (15%)
60	-	5 (62%)	3 (38%)
70	-	-	8 (100%)

Grade 40 ulcers showed predominantly nebular opacity (66.6%). Grade 50 ulcers showed predominantly macular opacity (85%). In grade 60 ulcers, majority (62%) were macular opacities but a major portion was of leucomatous opacities also (38%). In grade 70 ulcers only leucomatous opacities were formed.

OBSERVATION AND RESULTS

In our series the incidence of patients using antibiotics-steroid was 36.6% and same with the observations of P.siva reddy (1999)⁴ study - 39.0% patients using antibiotics-steroid (60%). The intraocular tension was found to be normal in 80% of cases in spite of a high incidence of hypopyon, these findings corresponds with the studies of Puttana (1995)⁵, Agarwal n Khosla (1995)⁶.

Vascularization was present in 40% of cases of mycotic ulcers of our series. it might have been due to a mixed infection in such cases, Agarwal n Khosla (1995) in the experimental study also found that addition of bacteria in case of mycotic ulcer led to early vascularisation of cornea. It was observed in our studies, that the grade of the ulcer were first seen was higher in those patients who have taken one form of treatment or other as compared to those who have not taken any treatment. This has been observed by many others, agarwal et al (1994)⁷ and agarwal and Khosla (1995) studied the role of topical antibiotics and steroids on mycotic ulcers in their experimental studies under controlled conditions. They found that the mycotic ulcers in which no treatment was given, increased gradually in size and depth and may even become static.

All the cases with 40% grade ulcers have not taken treatment before reporting to hospital. Here, the ulcer might have taken its natural course which is described as slow and indolent. Ulcers of 80% grade were not seen, but 13% ulcers were found to be in 90 to 100% grade. It may be due to the fact that after 70% grade the ulcer has the tendency to gallop leading to perforation. This is supported by the histopathological study of Panda et al (2003)⁸, but in advanced cases the fungus receives the descemets membrane and extends to the periphery of the cornea. In some case

The wet KOH mounts were positive for fungal hyphae in 58.6% cases which were positive culture. Our findings are in concurrence with those of Sharma S N (2000)⁹, Poria et al

(2003)¹⁰, who observed that KOH smears may be negative but growth will be seen on culture more so in cases of serious uncontrolled keratomycosis.

Sodium sulfacetamide (30%) was used in our study as an anti mycotic agent and it was observed that 24 cases showed healing of the ulcer. this indicates the efficacy of sodium sulfacetamide 30% in treating refractory mycotic ulcers. This is in agreement with the findings of Shrivastav U S et al(2001)¹¹ reported 79.09% incidence of healing with sulfa ointment and cautery.

CONCLUSION


Delay in seeking expert medical advice plays an important role in the genesis of mycotic keratitis. rural population seeks expert advice later than the urban population. Fungus can be grown on culture in majority of cases showing clinical features of mycotic keratitis and present with minimal symptoms and a suggestive history. Aspergillus is the commonest fungus encountered in this part of the country. Although wet KOH may be negative for fungus in many cases, growth may be seen on culture in these cases. The mycotic ulcers are central with dirty white elevated . Slough with or without hypopyon and satellite lesions. Intraocular tension remains normal in majority of cases. Vascularisation in such cases decrease the incidence as well as rate of healing. The importance of early treatment in mycotic keratitis is emphasized. The indiscriminate use of various forms of treatment ,especially antibiotics and steroids favor corneal ulcers. Combined use of antibiotics and steroids is more dangerous than use of only antibiotics. Sodium sulfacetamide 30% is an effective antimycotic agent this is of particular significance in our country where mycotic keratitis is more frequent in rural areas and laboratory facilities for identification and sensitivity testing are lacking. Apart from possessing all the properties of ideal antimycotic agent ,it is widely available in rural areas ;is inexpensive and easy to use; effective against many bacteria ;has high antitrachoma property and is markedly effective against Aspergillus infection which is most commonly encountered in mycotic keratitis..

Recently silver sulfacetamide has been found to be more effective in mycotic keratitis .

REFERENCE

1. Anderson B., Roberts ., jr. gonzalez C. , and Chick E.W., : 1995 , A.M.A. Arch.ophthal.,62:169-179.
2. Foster R.K. and Gerbert Rebell,:1999,arch. Of ophthal.,93:975.
3. Ajello , Georg ,Kaplan and Kauffmann,:1996,Laboratory manual for medical mycology ,U.S. dept. of health ,education and welfare,Atlanta,A-16.
4. P.Siva reddy,Satyendran O.M.,Satpathy M.,Vijaya kumar H.,and P.Ranga reddy,:1998,Ind, J. ophthalmology.20:101.

5. Puttana ST.1995,Proc. of trans -asia-pacific acad. of ophthalmology.
6. .Agarwal L.P. and khosla P.K. :1996,Ind.J.Ophthal.,15:1.
7. Agarwal L. P.,Malik S.R.K. ,Mohan M. and khosla P.K.,: 1995 . Brit.J.Ophthal.,47:109.
8. PandaA. ,madn mohan and mukherjee G.,:2004,Ind.j.Ophthalmology 32:311.
9. Sharma S.N,:2001.
10. Poria V.C. ,bharat V.R.,ka\ulkarni M.V,Ind. J. ophthal. 33:v:229.
11. Shrivastav US, Jain Ak, and singh VP,:2003,Ind J of Ophthal:24:1:19



BJMHR is

- **Peer reviewed**
- **Monthly**
- **Rapid publication**
- **Submit your next manuscript at**

editor@bjmhr.com

