

**BJMHR**British Journal of Medical and Health Research  
Journal home page: [www.bjmhr.com](http://www.bjmhr.com)

## Diffuse Unilateral Subacute Neuroretinitis: A Case Report

**Dr Prabha Sonwani<sup>1\*</sup>, Dr Suchita Singh<sup>2</sup>, Dr Rahul Chaudhary<sup>3</sup>***1.Asst. Professor, Department of Ophthalmology, CIMS, Bilaspur (C.G.)**2.Asso. Professor and HOD, Dept. Of Ophthalmology, CIMS, Bilaspur (C.G.)**3.Post graduate Resident, Dept. Of Ophthalmology, CIMS, Bilaspur (C.G.)*

### ABSTRACT

Diffuse unilateral subacute neuroretinitis (DUSN) represents an ocular infectious disease capable of precipitating severe visual impairment and, in some cases, blindness. It predominantly affects healthy young individuals, manifesting in various stages, which may include vitritis, multifocal Gray-white lesions in the outer retina, derangement of the retinal pigment epithelium, and narrowing of the retinal vessels, among other symptoms. The etiologic agent of DUSN encompasses parasites of varying sizes and species, such as *Ancylostoma caninum*, *Toxocara canis*, and others. Consequently, it is postulated that diverse infectious worms may be implicated in both the autoimmune and toxic forms of nematode retinopathy. Given the variability of serologic testing, a definitive diagnosis is established when clinical characteristics of DUSN are observed in conjunction with the presence of an intraocular worm. Additional diagnostic tools, including fluorescein and indocyanine green angiography, electrophysiological tests, visual field studies, and more recently, optical coherence tomography angiography, can aid in the differential diagnosis when the nematode cannot be directly visualized. In cases where the worm is identified, it is classified as confirmed DUSN, whereas eyes exhibiting typical clinical features but lacking worm identification are categorized as presumed DUSN. The standard treatment for confirmed DUSN involves direct photocoagulation of the worm, although its visualization is observed in only 30% to 40% of cases. Treatment of presumed DUSN with high-dose oral Albendazole has demonstrated promising outcomes. However, the rarity of the disease or its underdiagnosis may contribute to the lack of comparative studies evaluating the efficacy of current treatment modalities in both presumed and confirmed DUSN. Given the potential for DUSN to be, in part, an autoimmune form of nematode retinopathy, the use of corticosteroids in conjunction with Albendazole or laser therapy may prove beneficial. Therefore, further comparative studies are imperative to determine the most effective treatment approach for this potentially blinding condition.

**Keywords:** Albendazole, Diffuse unilateral subacute neuroretinitis (DUSN)

\*Corresponding Author Email: [prabhasonwani777@gmail.com](mailto:prabhasonwani777@gmail.com)

Received 22 June 2024, Accepted 16 July 2024

## INTRODUCTION

Diffuse unilateral subacute neuroretinitis (DUSN) represents an ocular infectious condition that may precipitate visual impairment and, in severe cases, blindness. The disease was initially delineated by Gass in 1978 [1], during which it was observed that healthy young individuals exhibited a gradual, often severe, unilateral visual loss, accompanied by vitritis and a diffuse, as well as focal, derangement of the pigment epithelial cells in the initial stages. Should the inflammation persist without treatment, the disease may progress to cause the narrowing of retinal vessels and optic atrophy, culminating in irreversible vision loss. Although DUSN is predominantly characterized as a unilateral condition, there have been reported instances of rare bilateral cases in the medical literature [1–6].

DUSN, is a condition characterized by inflammation and degeneration in the neurosensory retina and the retinal pigment epithelium (RPE), caused by a nematode worm whose exact pathogenetic mechanisms remain largely unknown. The first documented instances of this infection within the eye were reported in the year 1950 by Wilder [7], who observed the presence of nematodes in the enucleated eye tissue. Parsons [8] followed suit with the first detailed description of a subretinal worm species responsible for ocular syndrome in 1952. The earliest case of Brazil involving this worm was recorded in the early 1990s, spanning from 1990 to the early 2000s.

It has been noted that the presence of a subretinal worm is seen in less than half of the diagnosed cases, with the majority of these individuals being under the age of 20 and exhibiting significant visual impairment. This typically arises in later stages of the disease, where there is a reduced chance of visual improvement despite treatment. However, with early diagnosis and treatment initiated promptly, either through oral anti-helminthic medications or direct photocoagulation procedures to remove the worm, there has been documented improvement in vision and a more positive prognosis observed in some patients. The aim of this article is to comprehensively outline the symptoms and causes of DUSN, its underlying mechanisms, methods of diagnosis, and the current approaches to treatment.

## CASE REPORT:

A 49-year-old female came to our eye OPD with complaint of progressive painless diminution of vision in left eye and headache in the past 1 month.

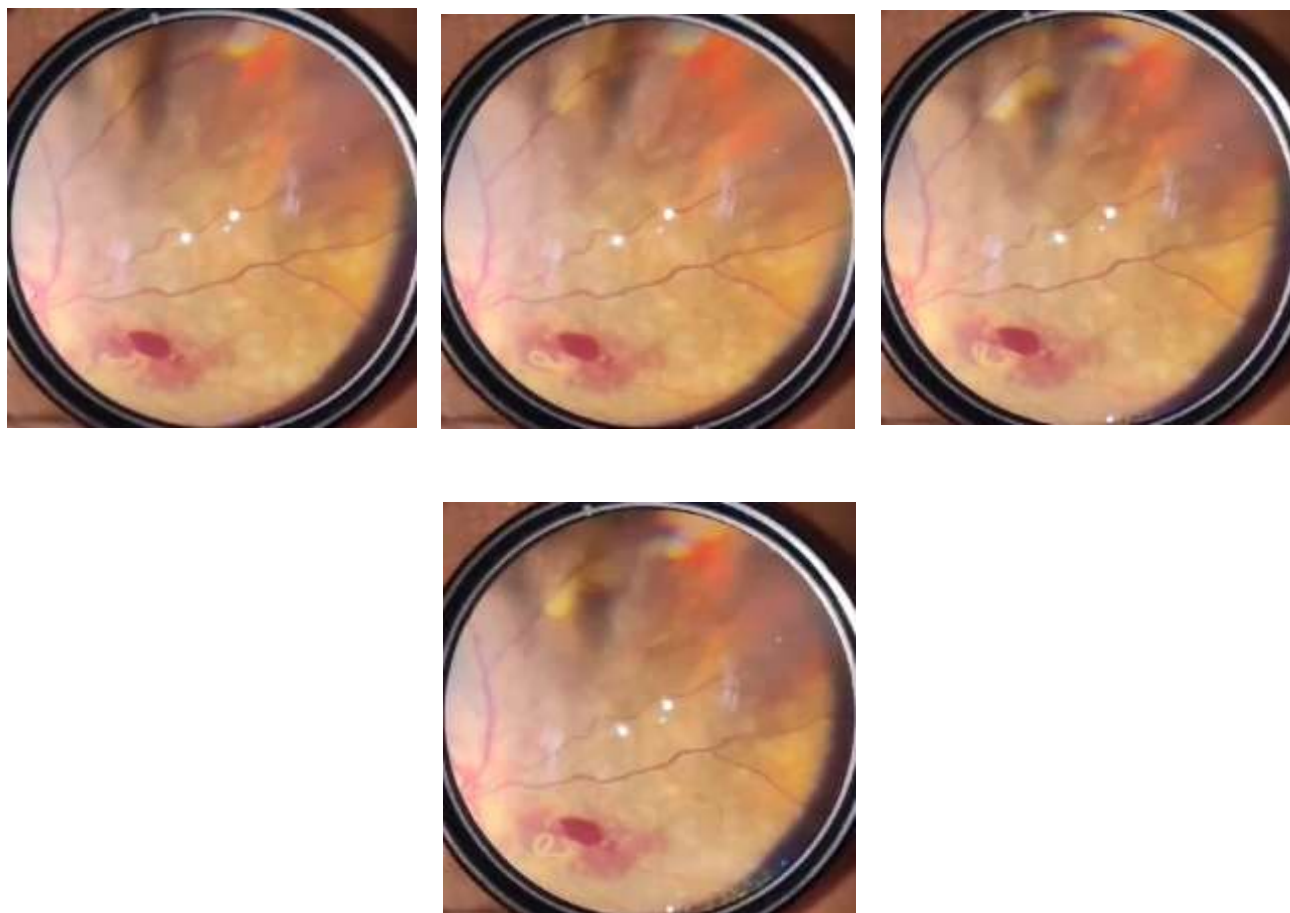
Patient was apparently alright 1 month ago when she started noticing diminution of vision in her left eye which was sudden, painless and progressive and also developed headache which was dull, intermittent and non-radiating in nature.

Patient had no history of fever, nausea, vomiting, seizure episode.

Patient gave history of mixed diet; disturbed sleep cycle and bowel and bladder habits were normal.

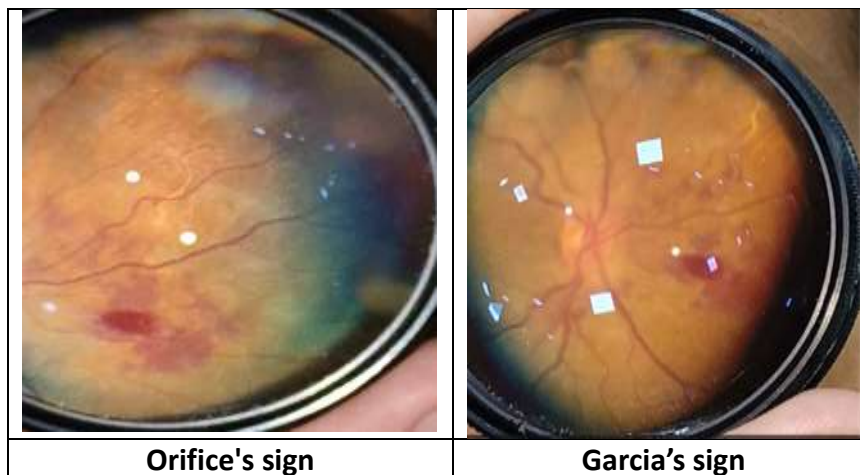
Patient resided in rural background in Bilaspur district, Chhattisgarh, India.

Examination	OD	OS
VA(Snellen's)	6/9	H.M.+ PR accurate
External	Normal lid and cilia	Normal lid and cilia
Conjunctiva	Clear	Clear
Cornea	Bright	Bright
Anterior Chamber	Depth normal content clear	Depth normal content clear
Iris/Pupil	Central circular reactive to light	RAPD Grade 1
Lens	Transparent	Transparent
Fundus	Media clear, 0.3 cup disc ratio, neuroretinal rim intact, FR +, rest fundus within normal limits.	Hyperemic disc with disc edema and diffuse disc margins along with tortuous vessels and venous engorgement with macular hemorrhage and multiple patches of sub hyaloid and subretinal hemorrhages with 1 motile larva in subretinal spaces.



**Figure 1.1-1.4: - Simultaneous fundus images showing motility of ocular larva lodged in subretinal space with pre-retinal and subretinal hemorrhages.**

Live nematode larva showing subretinal tunnel (Garcia's sign), increased internal membrane reflex (orifice's sign) with sub hyaloid hemorrhage and macular hemorrhage.



## INVESTIGATIONS:

Random blood sugar- 77mg/dl

Liver function test, Renal function test, lipid profile- Within normal limits.

Hemoglobin- 12.4 gm%

Viral markers – negative

Urine- routine and microbiology- Within normal limits

Stool examination- showed cyst of entamoeba histolytica seen with few pus cells.

B-scan- left eye heterogeneity noted in the posterior chamber adjacent to optic disc

USG- abdomen- Grade 1 fatty liver with mild hepatomegaly

MRI brain + orbit + pns + chest- deviated nasal septum with convexity towards left seen and no other significant abnormality seen in orbit.

## Management:

Treatment was started with

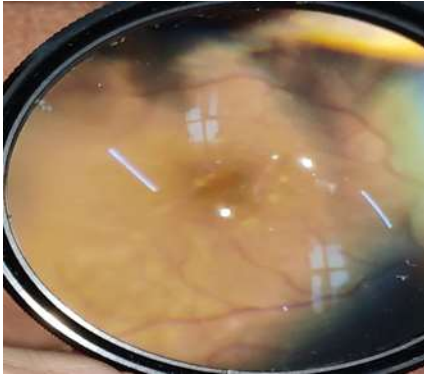
- Tablet albendazole 400mg od for 1 month
- Tablet diethylcarbamazine 1gm STAT dose given in 3 divided doses
- Tablet Prednisolone 50 mg tapering over by 10 mg in every 6th day and progression was monitored on daily basis.

Larva became immobile on day 3 after starting tab. Albendazole with improvement in visual acuity.

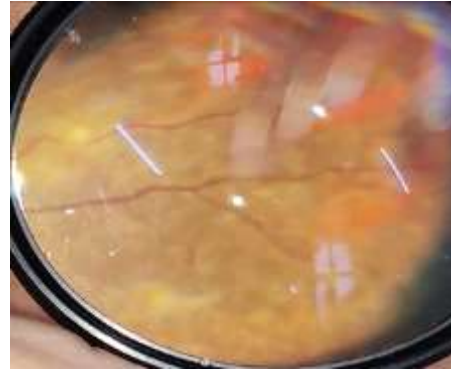
Patient was planned for laser photocoagulation.

## Post Intervention: -

Patient was followed at 1 month with Visual acuity improving to 6/36, on fundus examination it showed resolution of disc edema and subretinal hemorrhages with presentation of subretinal fibrosis.



1 month follow up showing resolved macular hemorrhage with subretinal fibrosis



1 month follow up showing multiple patches of resolved subretinal and sub hyaloid hemorrhages with subretinal fibrosis and chorioretinitis.

## DISCUSSION:

The onset of Diffuse unilateral subacute neuroretinitis (DUSN) is often associated with the presence of a larva in the subretinal space, which induces a profound inflammatory and degenerative process affecting both the retina and the retinal pigment epithelium (RPE). This process is characterized by the infiltration of eosinophils, macrophage aggregates, and gliosis, which can impact all layers of the retina, resulting in a variable loss of ganglion cells. The toxic substances excreted by the larva in the subretinal space may directly affect the external retina, leading to a widespread tissue reaction that can cause damage to both the internal and external retina. As the disease progresses, there is a narrowing of the retinal vessels, and there is a gradual loss of ganglion cells until ultimately, optic atrophy is established.

Therefore, the primary pathophysiological mechanisms underlying DUSN are thought to involve the migration of the worm through the neurosensory retina, the toxicity of its excretions, and the host's immune response. These mechanisms converge to form a toxic autoimmune nematode retinopathy. DUSN is most commonly observed in healthy children or young adults with no significant ocular history. The clinical presentation of DUSN varies depending on the stage of the disease, which can be categorized as early or late, and can manifest as transient, multifocal Gray-white lesions at the level of the outer retina and choroid. These lesions often cluster in one segment of the fundus and are thought to be related to possible reactions to the nematode in the subretinal space. These lesions are believed to migrate and change in response to the location of the worm. The lesions may or may not leave a residual retinal lesion, depending on the degree of the host's immune response to the toxic products of the worm.

As the worm progresses and migrates to another area of the retina, the initial lesions may fade, which explains the transient nature of these Gray-white lesions and their reappearance in different locations. Visual loss is typically irreversible and is usually more severe than

20/200 in about half of the patients. Central or paracentral scotomas (areas of vision loss) may also be present. In approximately 25 to 40% of cases, an intraocular worm is detected during the eye examination. The worm is observed as a mobile, white nematode varying in length from 400 to 2000µm. Some species of worm are more sensitive to light, which can cause the worm to move when examining the light from a slit lamp, a behaviour that may be particularly useful in cases where the worms are located in the macula, as it can facilitate their removal through photocoagulation.

In the subsequent phases of the disease, patients may exhibit signs of mild vitritis, the presence of tunnels as delineated by optical coherence tomography (OCT), and both focal and diffuse degenerative alterations within the pigment epithelium (RPE) and the retinal layer. The subretinal space may show signs of Garcia's sign, optical coherence tomography, which is indicative of tunnel formation. This is accompanied by varying degrees of subretinal venous engorgement, macular cysts, localized retinal detachment, and the development of neovascularization within the subretinal space [2, 3, 31, 35].

During the advanced stages of the disease, patients may present with mild vitritis. Additionally, ocular signs such as the presence of tunnels, as confirmed by OCT, are frequently observed, along with focal and diffuse degenerative changes within the RPE and retinal layers. This stage is characterized by the narrowing of retinal arterioles across different quadrants, in conjunction with the atrophy of the optic disc, leading to irreversible loss of vision. Vision may be significantly affected, with 80% or more of patients experiencing visual acuity of 20/200 or worse. The retina undergoes both diffuse and focal depigmentation, which is most noticeable in the peripheral and peripapillary regions. In contrast, less severe changes are observed within the central macular area. This stage of the disease is marked by significant changes within the RPE layers, which can have lasting effects on vision.

## CONCLUSION:

Regardless of the nature of the causative organism, and if it the nematode can be visualized or not, DUSN should always be suspected in healthy patients with unilateral insidious loss of vision, vitreous inflammation, retinal vasculitis, multifocal lesions involving deep retinal layers, narrowing of the retinal vessels, or optic atrophy. Laser photocoagulation offers the best chance for clinical resolution of the disease, but the worm is visualized in only a small portion of the cases, in which other treatments such as high-dose Albendazole have been used with efficacy and safety; however, the optimal treatments' dose and duration has still not been determined. Despite this, it is very important to establish the diagnosis in the early phase when worm photocoagulation or oral antihelminthic has the greatest likelihood of vision

improvement. In the literature, there are no studies comparing treatment's regimen in both presumed and confirmed DUSN. Due to the possibility of this disease having an immunological element, corticosteroids associated with both high-dose Albendazole and laser therapy could be in any way beneficial. Thus, further studies are necessary to better elucidate the efficacy of current treatment modalities and its associations depending on the stage of this potentially blinding disease.

## DECLARATION OF PATIENT CONSENT

The authors certify that they have obtained all appropriate patient consent forms. In the form the patient(s) has/have given his/her/their consent for his/her/their images and other clinical information to be reported in the journal. The patients understand that their names and initials will not be published and due efforts will be made to conceal their identity, but anonymity cannot be guaranteed.

## REFERENCES

1. Gass JD, Scelfo R. Diffuse unilateral subacute neuroretinitis. *Journal of the Royal Society of Medicine*. 1978; 71(2):95–111. doi: 10.1177/014107687807100205. [PMC free article] [PubMed] [CrossRef] [Google Scholar]
2. Barney NP. Diffuse unilateral subacute neuroretinitis. In: Foster CS, Vitale AT, editors. *Diagnosis and treatment of uveitis*. 1. Philadelphia: W.B. Saunders; 2002. pp. 475–479. [Google Scholar]
3. Arevalo JF, Arevalo FA, Garcia RA, de Amorim Garcia Filho CA, de Amorim Garcia CA. Diffuse unilateral subacute neuroretinitis. *Journal of pediatric ophthalmology and strabismus*. 2013;50(4):204–212. doi: 10.3928/01913913-20121211-03. [PubMed] [CrossRef] [Google Scholar]
4. de Souza EC, Abujamra S, Nakashima Y, Gass JD. Diffuse bilateral subacute neuroretinitis: first patient with documented nematodes in both eyes. *Archives of ophthalmology (Chicago, Ill : 1960)*. 1999;117(10):1349-1351. [PubMed]
5. Mets MB, Noble AG, Basti S, Gavin P, Davis AT, Shulman ST, et al. Eye findings of diffuse unilateral subacute neuroretinitis and multiple choroidal infiltrates associated with neural larva migrans due to *Bbaylisascaris procyonis*. *American journal of ophthalmology*. 2003;135(6):888–890. doi: 10.1016/S0002-9394(02)01539-8. [PubMed] [CrossRef] [Google Scholar]
6. Sabrosa NA, de Souza EC. Nematode infections of the eye: toxocariasis and diffuse unilateral subacute neuroretinitis. *Current opinion in ophthalmology*. 2001;12(6):450–454. doi: 10.1097/00055735-200112000-00010. [PubMed] [CrossRef] [Google Scholar]

7. Wilder HC. Nematode endophthalmitis. *Trans Am Acad Ophthalmol Otolaryngol.* 1950;55:99–109. [PubMed] [Google Scholar]
8. Parsons HE. Nematode chorioretinitis; report of a case, with photographs of a viable worm. *AMA archives of ophthalmology.* 1952;47(6):799–800. doi: 10.1001/archophth.1952.01700030818011. [PubMed] [CrossRef] [Google Scholar]
9. Gass JDM, Olsen KR. Diffuse unilateral subacute neuroretinitis. In: Ryan SJ, Schachat AP, editors. *Retina.* 3. St. Louis, MO: Mosby; 2001. pp. 1669–1678. [Google Scholar]
10. Oliveira AA, Oréfice F. Estudo de sete casos de neuroretinite difusa subaguda unilateral. *Rev Bras Oftalmol.* 1991;51(1):51–55. doi: 10.1590/S1517-86922006000100010. [CrossRef] [Google Scholar]
11. Kazacos KR, Raymond LA, Kazacos EA, Vestre WA. The raccoon ascarid. A probable cause of human ocular larva migrans. *Ophthalmology.* 1985;92(12):1735–1744. doi: 10.1016/S0161-6420(85)34100-3. [PubMed] [CrossRef] [Google Scholar]
12. Kazacos KR, Vestre WA, Kazacos EA, Raymond LA. Diffuse unilateral subacute neuroretinitis syndrome: probable cause. *Archives of ophthalmology (Chicago, Ill: 1960).* 1984;102(7):967-968. [PubMed]
13. Kuchle M, Knorr HL, Medenblik-Frysch S, Weber A, Bauer C, Naumann GO. Diffuse unilateral subacute neuroretinitis syndrome in a German most likely caused by the raccoon roundworm, *Baylisascaris procyonis*. *Graefes Arch Clin Exp Ophthalmol.* 1993; 231(1):48–51. doi: 10.1007/BF01681701. [PubMed] [CrossRef] [Google Scholar]
14. Tarantola Ryan M. Photoreceptor Recovery Following Laser Photocoagulation and Albendazole in Diffuse Unilateral Subacute Neuroretinitis. *Archives of Ophthalmology.* 2011;129(5):664. doi: 10.1001/archophthalmol.2011.93. [PubMed] [CrossRef] [Google Scholar]
15. Audo I, Webster AR, Bird AC, Holder GE, Kidd MN. Progressive retinal dysfunction in diffuse unilateral subacute neuroretinitis. *The British journal of ophthalmology.* 2006;90(6):793–794. doi: 10.1136/bjo.2005.085548. [PMC free article] [PubMed] [CrossRef] [Google Scholar]
16. de Amorim Garcia Filho Carlos Alexandre, Gomes Alexandre Henrique Bezerra, de A. Garcia Soares Ana Claudia M., de Amorim Garcia Carlos Alexandre. Clinical Features of 121 Patients with Diffuse Unilateral Subacute Neuroretinitis. *American*

- Journal of Ophthalmology. 2012;153(4):743–749. doi: 10.1016/j.ajo.2011.09.015. [PubMed] [CrossRef] [Google Scholar]
17. Rosa AA, Rodrigues Neto Tdos S. [Diffuse unilateral subacute neuroretinitis (DUSN): current update] *Arquivos brasileiros de oftalmologia*. 2013;76(4):256–260. doi: 10.1590/S0004-27492013000400016. [PubMed] [CrossRef] [Google Scholar]
  18. Souza EC, Casella AM, Nakashima Y, Monteiro ML. Clinical features and outcomes of patients with diffuse unilateral subacute neuroretinitis treated with oral albendazole. *American journal of ophthalmology*. 2005;140(3):437–445. doi: 10.1016/j.ajo.2005.03.065. [PubMed] [CrossRef] [Google Scholar]
  19. Garcia CA, Sabrosa NA, Gomes AB, Segundo Pde S, Garcia Filho CA, Sabrosa AS. Diffuse unilateral subacute neuroretinitis--DUSN. *International ophthalmology clinics*. 2008;48(3):119–129. doi: 10.1097/IIO.0b013e31817d9a2a. [PubMed] [CrossRef] [Google Scholar]
  20. Gass JD, Braunstein RA. Further observations concerning the diffuse unilateral subacute neuroretinitis syndrome. *Archives of ophthalmology (Chicago, Ill : 1960)*. 1983;101(11):1689-1697. [PubMed]
  21. Moraes Lúcio R. Identifying Live Nematodes in Diffuse Unilateral Subacute Neuroretinitis by Using the Scanning Laser Ophthalmoscope. *Archives of Ophthalmology*. 2002;120(2):135. doi: 10.1001/archophth.120.2.135. [PubMed] [CrossRef] [Google Scholar]
  22. de Souza EC, Nakashima Y. Diffuse unilateral subacute neuroretinitis. Report of transvitreal surgical removal of a subretinal nematode. *Ophthalmology*. 1995;102(8):1183–1186. doi: 10.1016/S0161-6420(95)30892-5. [PubMed] [CrossRef] [Google Scholar]
  23. Oréface F, Gonçalves ER, Siqueira RC, et al. Estudo de 21 casos de Neuroretinite subaguda unilateral difusa (DUSN)-dois casos de larva móvel sub-retiniana. *Ver Bras Oftalmol*. 1994;53:467–489. [Google Scholar]
  24. Oppenheim S, Rogell G, Peyser R. Diffuse unilateral subacute neuroretinitis. *Annals of ophthalmology*. 1985;17(6):336–338. [PubMed] [Google Scholar]
  25. Goldberg MA, Kazacos KR, Boyce WM, Ai E, Katz B. Diffuse unilateral subacute neuroretinitis. Morphometric, serologic, and epidemiologic support for *Baylisascaris* as a causative agent. *Ophthalmology*. 1993;100(11):1695–1701. doi: 10.1016/S0161-6420(93)31415-6. [PubMed] [CrossRef] [Google Scholar]
  26. Kazacos KR, Boyce WM. *Baylisascaris larva migrans*. *Journal of the American Veterinary Medical Association*. 1989; 195(7):894–903. [PubMed] [Google Scholar]

27. Gass JDM. Diffuse unilateral subacute neuroretinitis. In: Gass JDM, editor. Stereoscopic atlas of macular diseases: diagnosis and treatment. 4. St. Louis: Mosby-Year Book Inc; 1997. pp. 622–628. [Google Scholar]
28. Oréfice F, Bonfi Oli AA, FRL P. Diffuse unilateral subacute neuroretinitis. In: Oréfice F, editor. Uveitis: Clinical and Surgical. Rio de Janeiro, Brazil: Cultura Médica; 1998. pp. 733–756. [Google Scholar]
29. Carney MD, Combs JL. Diffuse unilateral subacute neuroretinitis. The British journal of ophthalmology. 1991;75(10):633–635. doi: 10.1136/bjo.75.10.633. [PMC free article] [PubMed] [CrossRef] [Google Scholar]
30. Berbel RF, Casella AM, de Souza EC, Farah ME. Evaluation of patients with diffuse unilateral subacute neuroretinitis by spectral domain optical coherence tomography with enhanced depth imaging. Clinical ophthalmology. 2014;8:1081–1087. [PMC free article] [PubMed] [Google Scholar]
31. Cortez RT, Ramirez G, Collet L, Giuliari GP. Ocular parasitic diseases: a review on toxocariasis and diffuse unilateral subacute neuroretinitis. Journal of pediatric ophthalmology and strabismus. 2011;48(4):204–212. doi: 10.3928/01913913-20100719-02. [PubMed] [CrossRef] [Google Scholar]
32. Relhan N, Pathengay A, Raval V, Nayak S, Choudhury H, Flynn HW., Jr Clinical experience in treatment of diffuse unilateral subretinal neuroretinitis. Clinical ophthalmology. 2015; 9:1799–1805. doi: 10.2147/OPHTH.S86989. [PMC free article] [PubMed] [CrossRef] [Google Scholar]
33. de Souza EC, da Cunha SL, Gass JD. Diffuse unilateral subacute neuroretinitis in South America. Archives of ophthalmology (Chicago, Ill : 1960). 1992;110(9):1261-1263. [PubMed]
34. Garcia CA, Gomes AH, Garcia Filho CA, Vianna RN. Early-stage diffuse unilateral subacute neuroretinitis: improvement of vision after photocoagulation of the worm. Eye. 2004;18(6):624–627. doi: 10.1038/sj.eye.6700742. [PubMed] [CrossRef] [Google Scholar]
35. Garcia CA, de Oliveira AG, de Lima CE, Rocha FN, Garcia Filho CA. Retinal nerve fiber layer analysis using GDx in 49 patients with chronic phase DUSN. Arquivos brasileiros de oftalmologia. 2006;69(5):631–635. doi: 10.1590/S0004-27492006000500002. [PubMed] [CrossRef] [Google Scholar]
36. Casella AM, Farah ME, Souza EC, Belfort R, Jr, Oguido AP. Retinal nerve fiber layer atrophy as relevant feature for diffuse unilateral subacute neuroretinitis (DUSN): case

series. Arquivos brasileiros de oftalmologia. 2010;73(2):182–185.  
doi: 10.1590/S0004-27492010000200017. [PubMed] [CrossRef] [Google Scholar]

**BJMHR is**

- **Peer reviewed**
- **Monthly**
- **Rapid publication**
- **Submit your next manuscript at**

**editor@bjmhr.com**

